

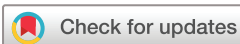Prevalence of achlorhydria in an Asian population detected using Congo red staining during routine gastroscopy: 22 years' experience from a single centre

Kamthorn Phaosawasdi,¹ Yingluk Sritunyarat,² Chawin Lopimpisuth ,² Nutbordee Nalinthassanai,² Yongkasem Vorasettakarnkij,³ Pradermchai Kongkam^{2,3}

To cite: Phaosawasdi K, Sritunyarat Y, Lopimpisuth C, *et al*. Prevalence of achlorhydria in an Asian population detected using Congo red staining during routine gastroscopy: 22 years' experience from a single centre. *BMJ Open Gastro* 2022;**9**:e000976. doi:10.1136/bmjgast-2022-000976

► Additional supplemental material is published online only. To view, please visit the journal online (<http://dx.doi.org/10.1136/bmjgast-2022-000976>).

Received 11 June 2022
Accepted 10 August 2022



© Author(s) (or their employer(s)) 2022. Re-use permitted under CC BY-NC. No commercial re-use. See rights and permissions. Published by BMJ.

¹Gastrointestinal and Liver Clinic and Endoscopy Unit, Vichaiyut Hospital, Bangkok, Thailand

²Excellence Center for Gastrointestinal Endoscopy, King Chulalongkorn Memorial Hospital, Bangkok, Thailand

³Department of Medicine, Division of Hospital and Ambulatory Medicine, Chulalongkorn University Faculty of Medicine, Bangkok, Thailand

Correspondence to

Dr Pradermchai Kongkam; kongkam@hotmail.com

ABSTRACT

Objective We aimed to study the prevalence of achlorhydria (AC) in a large Asian population.

Design Medical records of patients who underwent oesophagogastroduodenoscopy (OGD) with Congo red staining method at the Vichaiyut Hospital from January 2010 to December 2019 were retrospectively reviewed.

Results A total of 3597 patients was recruited; 223 were excluded due to concurrent use of proton pump inhibitors. Eighteen from 3374 patients (0.53%) had AC. Seven patients were presented with permanent AC (5F, 2M) (median age=69 years; range 58–92). Among 11 patients with temporary AC (5M, 6F: mean age 73.4 years; SD 13.2 years), all had gastrointestinal *Helicobacter pylori* bacterial infection and were over 45 years old. After successful treatment for *H. pylori*, AC was absent among patients with temporary AC. If counting only patients over 45 years of age, the prevalence of AC was 0.68% (18/2614). No adverse events arising from Congo red occurred.

Conclusion AC is relatively rare. Permanent and temporary AC were found only when they were over 55 and 45 years old, respectively. Staining Congo red on gastric mucosa can be safely and routinely incorporated into the OGD procedure for early detection of AC. We recommended a low-cost screening test such as serum vitamin B levels for screening only in patients aged 50 and over.

INTRODUCTION

Achlorhydria (AC) refers to a state in which the stomach is unable to produce hydrochloric acid, which is a significant component of gastric secretions produced by the stomach. The acid digests food and protects the body from foodborne pathogens. Gastric acid are fluids secreted by the stomach, consisting of hydrochloric acid, potassium chloride and sodium chloride. Parietal cells lining the stomach wall are the cells responsible for producing gastric acid. Various factors can damage these cells include surgery, bacteria (*Helicobacter pylori*),

WHAT IS ALREADY KNOWN ON THIS TOPIC

- ⇒ Achlorhydria (AC) is relatively rare.
- ⇒ Prevalence of AC has been reported in only small and selective samples of patients.
- ⇒ Early detection of AC can prevent irreversible brain damage from pernicious anaemia which can lead to irreversible neurological deficit.
- ⇒ Gastroscopy has been increasingly used worldwide.
- ⇒ Congo red testing during gastroscopy can be simply used to identify AC on-site.

WHAT THIS STUDY ADDS

- ⇒ In our study, AC is only present in patients over 45 years of age.
- ⇒ Our prevalence of AC from a large Asian population is demonstrated to be rarer than previously reported from Western country.
- ⇒ Systematic use of Congo red testing during oesophagogastroduodenoscopy can be done with little to no extra burden or adverse events as shown by two-decade procedural implementation.
- ⇒ All patients with permanent AC in our study were aged 55 years or older at the time of diagnosis.
- ⇒ Given the low prevalence of the AC, although it can cause a serious complication, we recommend a low-cost screening test such as serum vitamin B₁₂ levels for screening only in patients aged 50 and over.

HOW THIS STUDY MIGHT AFFECT RESEARCH, PRACTICE, OR POLICY

- ⇒ This present study shows that AC is rare, seen only in patients over 50 years of age. Screening is quick and easy with the Congo red test during an upper gastrointestinal endoscopy. The information from this current study is therefore one of the important pieces of information to be taken into consideration regarding screening policy for the disease: should doctors consider screening methods for this disease in the future? To our knowledge, no study of the disease in such a large number of Asian ethnicities has been reported before.

medication and certain antibodies which may lead to AC among patients.

AC can be categorised into two groups based on its causes: (1) permanent achlorhydria (permanent AC), whose condition is irreversible; and (2) temporary achlorhydria (temporary AC), whose cause or association with certain diseases can be cured. One example being infection with *H. pylori* in the stomach and using a proton pump inhibitor.

AC can lead to several diseases or conditions. One condition is pernicious anaemia (PA) where the process of vitamin B₁₂ absorption has been altered. The presence of PA leads to irreversible neurological deficits, which includes the following neurological symptoms: personality changes, cognitive impairment, paresthesia, psychosis, dementia, weakness of muscle, paraplegia and urinary incontinence. Detecting AC is crucial since remedies are often available.

Diagnostic techniques for AC can be performed in a number of ways. One simple method is to diagnose while the physician is performing an oesophagogastroduodenoscopy (OGD). This method involves staining Congo red on the gastric mucosa. Congo red is pH sensitive and changes its colour from red to dark blue or black in an acidic environment which is the body's normal condition. When patients have AC, Congo red does not change colour. Staining the gastric mucosa only takes a few additional minutes during OGD. Congo red can be completely washed off with normal rinse. The use of dye in the digestive tract is not harmful to the body.

In this current study, researchers collected data from a large referral hospital in Thailand which has incorporated Congo red staining of gastric mucosa as protocol during OGD since 1998. The procedure was performed in all patients who had undergone OGD with no contraindications for the use of Congo red for staining of gastric mucosa. The primary objective is to determine the prevalence of AC among this population with a secondary objective to identify the clinical features of patients with AC. Ascertainment of the likely cause of AC in each patient will also be investigated.

METHODS

Medical records inspection

This study conducted a large single-centre retrospective examination of medical records of patients that underwent OGD at Vichaiyut Hospital in Bangkok, Thailand from January 1998 to December 2019. Inclusion criteria were patients undergoing successful OGD by means of various indications and staining of gastric mucosa with Congo red. Exclusion criteria were patients taking either a proton pump inhibitor or histamine receptor antagonist within 2 weeks before the procedure. For patients with positive Congo red results, researchers conducted a comprehensive review of patient data including the results of the OGD, results of gastric mucosa staining and clinical background information. The data were then

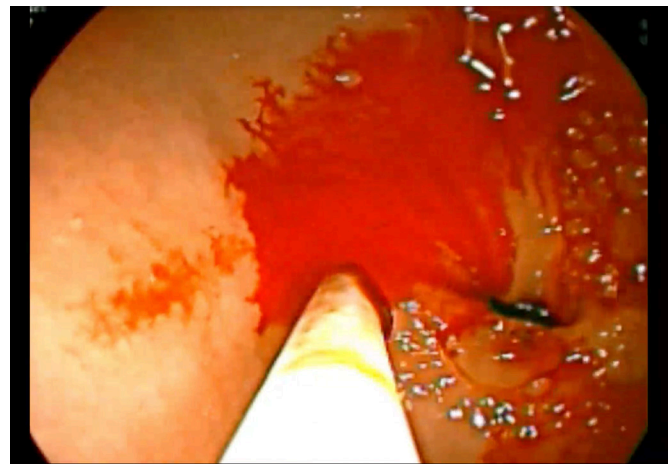


Figure 1 Congo red does not change its colour because there is no acid on gastric mucosa.

summarised and analysed. The protocol was approved by the Ethics Committee of the Vichaiyut Hospital.

Procedure for detection of AC using Congo red

While performing the routine OGD, the following sequence of steps are taken. The physician inserts a gastro-scope into the patient's upper digestive area to check the mucosa of the stomach and duodenum to determine if there are cancerous or non-cancerous lesions. A small tube is then inserted through the instrument channel of the gastro-scope to protrude into the stomach area. A 10cc syringe containing Congo red paint is sprayed through the rubber tube on the gastric mucosa in the body of the stomach. Through visual identification, any colour change of the gastric mucosa is identified. The diagnostic criterion for AC is no change in the colour of Congo red (**figure 1**). If Congo red is exposed to acidic conditions, the colour will change from red (pH 5.0) to dark blue or black (pH 3.0) (**figure 2**; online supplemental videos 1 and 2, respectively).



Figure 2 Congo red changes its colour from red to dark blue or black in an acidic environment.

Monitoring and isolating patients with AC

According to protocols at Vichaiyut Hospital, patients confirmed with AC were advised that determination of the cause according to clinical information from history taking, physical examination and further inspection would be undertaken. Physicians would also recommend for patients to attend regular follow-up appointments to treat AC and its underlying causes. Further inspection recommended by the physician included pathological examination of the gastric mucosa, gastrin level, *H. pylori* infection and vitamin B₁₂ blood test.

Results obtained from the examination and extracted from the patient records were studied by the researchers. The patients were divided into two groups: the first group included patients with permanent AC. Due to the unknown aetiology of permanent AC, this group of patients was treated with vitamin B₁₂ to prevent complications such as neurological deficits and anaemia. The second group included patients with temporary AC who were treated and received follow-up examinations to determine if AC and the diseases which caused it had improved. If the physician was unable to treat the cause of the disease or the treatment took a long time, the physician would also treat AC with B₁₂ supplements to prevent complications from such a condition.

Statistical analysis

The researchers presented demographic and clinical characteristics of individuals found with AC using counts and percentages. Prevalence calculations are presented as a number and percentage. No statistical tests were performed.

RESULTS OF STUDY

A review of medical records at Vichaiyut Hospital from January 1998 to December 2019 revealed that a total of 3597 patients had undergone OGD and the Congo red method. All patients met the inclusion criteria; 223 were excluded due to concurrent use of proton pump inhibitors or histamine receptor antagonists within 2 weeks before the procedure. Eventually, 3374 were recruited in the study. A total of 18 patients were found to have had AC, 7 of whom were categorised as permanent AC and 11 as temporary AC. The total prevalence of AC among subjects was 0.53% (18/3374) (figure 3)

Clinical data on the seven patients with permanent AC are shown in table 1.

Five of the seven patients (71.4%) with permanent AC were women and two (38.6%) were men. The mean age of patients at diagnosis time was 74.6 years (SD 11.9). The second patient who tested positive for *H. pylori* infection was categorised as having permanent AC since AC could still be detected after successful treatment for *H. pylori*. All patients were found to have high levels of serum gastrin (median=3000 pg/mL; range=1300–3000 pg/mL). All patients in this group were confirmed with

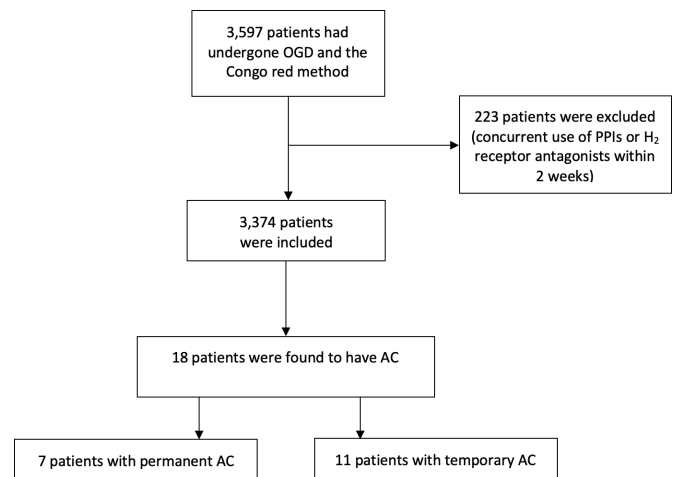


Figure 3 Diagram showing flow and number of patients involved in this current study. AC, achlorhydria; OGD, oesophagogastroduodenoscopy; PPI, proton pump inhibitor.

intestinal metaplasia from pathological results from the gastric mucosa (table 2).

Clinical data on the 11 patients with temporary AC are shown in table 3.

Five were men (45%) and six were women (55%). Patients had a mean age of 73.4 years (SD 13.2 years). All patients in this group had gastrointestinal *H. pylori* bacterial infection while being examined with Congo red. After treatment for *H. pylori*, patients were re-examined with Congo red and AC was absent.

After completing an OGD at Vichaiyut Hospital, a follow-up typically would occur 1 day after a procedure was performed. The patient would either meet the physician or would be contacted via telephone by the nursing team or medical personnel to monitor their condition. Review of all data found that no patients had complications arising from the Congo red procedure in this study.

DISCUSSION

The present study included a large number of subjects from a single institution over a period of 10 years. To our knowledge, this present study has the largest number of participants. Past studies have a smaller population. Demographics tend to be niche populations that are more likely to be AC than the general population. It is therefore not surprising that the prevalence of AC in this current study was lower than that reported in other previous studies such as a prospective survey by Carmel *et al* that was conducted to determine cobalamin levels and anti-intrinsic factor antibodies in 729 people who were over 60 years of age. It was found that 14 of them were present with PA, which accounts for 1.9%. Most of the patients were asymptomatic with no anaemia.¹ Bins *et al* studied a blood test for serum gastrin levels after patients had been fully stimulated with pentagastrin. In the diagnosis of AC in the Bins *et al* study, the prevalence of AC was found to be 2.5%.² A prospective survey by Carmel *et al* was conducted to determine cobalamin levels and

**Table 1** Characteristics of patients with permanent AC

Patient number	Age (years)	Serum vitamin B ₁₂ (pg/mL) (normal value=187–883 pg/mL)	Anti-intrinsic factor	Serum gastrin level (pg/mL)
1	58	2000	Positive	2000
2	86	2000	Positive	3000
3	69	405	Positive	3000
4	69	224	Negative	1300
5	80	1642	Positive	3000
6	92	265	Positive	3000
7	68	100	Negative	2100

AC, achlorhydria.

anti-intrinsic factor antibodies in 729 people who were over 60 years of age. It was found that 14 of them were present with PA, which accounts for 1.9%. Most of the patients were asymptomatic with no anaemia.³ In the Jacobson *et al* study, the type of population was patients with autoimmune disease.⁴ The prevalence of AC from other studies has been estimated at 2%, while the prevalence of permanent AC in this study was 0.19%, a rate 10 times smaller. The reason for such a difference is that the types of studies and population were different, especially in terms of the groups or characteristics of the population who participated in the study.

Ethnicity is likely another factor since Asians have been found to have a lower prevalence of AC than other races according to past studies and our study was exclusively an Asian population. Data indicate that the prevalence of the disease varies between races. In a study of 156 patients in Europe, 73 patients were European in origin, mean age among black women (53±1) was lower than that of all the others, and another study found that Latin-American people with pernicious anaemia were both significantly younger than white men and women.¹⁵

One interesting information from the results of this study is that permanent AC is found only in the population aged 55 years and over, but including temporary AC, it is found only in the population aged 45 and over. This is an important issue because if we look at PA as a disease that causes disability and may be the cause of

death, and if we can diagnose in the first place before the patient has consequences of neurological diseases, treatment would be very easy with the cheap cost of treatment. Therefore, we should have a plan for screening for AC at an appropriate age of patients. However, there may be some objections that, given the low prevalence of the disease, screening tests are not appropriate. Nevertheless, if we look closely, we will find that screening for AC is very simple and cheap if not counting the endoscopic examination, which is the method used in this present research. Another interesting method is to test vitamin B₁₂ levels, which is easy, inexpensive and patients do not need an endoscopy. Considering this study's data which found that this disease is found only in patients aged 45 years and over, we may therefore have future studies to study whether it is worthwhile or not that we will only screen for AC in patients aged 50 years and over by using a cheap and easy way to do it in general such as checking vitamin B₁₂ levels, but at the same time, if the patient is required to undergo a gastroscopy, we may consider using Congo red test used in this current study. Nevertheless, the data presented in this current study, in fact, do not support that Congo red screening is appropriate as the very low detection rate suggests that it is not worthwhile. It seems to be more reasonable for us to suggest that vitamin B₁₂ screening may be an appropriate routine test in those with risk factors with age more than 50 years.

Table 2 Light microscopic finding among patients with permanent AC

Patient number	Finding	Pathology finding
1	Focal area of mild gastritis at body, fundus and antrum	Mild chronic gastritis with IM mature type
2	Focal area of mild gastritis at antrum	Mild chronic gastritis with IM mature type
3	Atrophic gastritis at body and fundus, mild gastritis at antrum	Mild chronic gastritis with IM mature type
4	Focal area of mild hyperemia at antrum	Mild chronic gastritis with IM mature type
5	Focal area of mild gastritis at antrum	Mild chronic gastritis with IM mature type
6	Focal area of mild gastritis at antrum	Mild chronic gastritis with IM mature type
7	Focal area of mild gastritis at antrum	Mild chronic gastritis with IM mature type

AC, achlorhydria; IM, intestinal metaplasia.

Table 3 Characteristics of patients with temporary AC

Patient number	Age	Sex	Serum gastrin (pg/mL)	HP status	Pathology finding
1	82	M	84	Positive	IM chronic gastritis
2	80	F	N/A	Positive	IM mature type with atrophic gastritis
3	65	M	N/A	Positive	Mild chronic gastritis
4	69	M	N/A	Positive	Mild antral gastritis with IM mature type
5	83	F	N/A	Positive	Mild chronic gastritis
6	54	M	480	Positive	Mild chronic gastritis
7	67	F	N/A	Positive	Chronic atrophic gastritis
8	80	F	N/A	Positive	HP-related gastritis
9	62	F	200	Positive	HP-related gastritis
10	64	M	96	Positive	HP-related gastritis
11	101	F	250	Positive	Mild chronic gastritis with IM mature type

AC, achlorhydria; HP, *Helicobacter pylori*; IM, intestinal metaplasia; N/A, not available.

This present study showed the use of the Congo red method during OGD, which is a very convenient way of diagnosing AC from gastric mucosa. The process can be carried out with ease and safety, taking only an additional few minutes during an OGD. The results are also immediately produced and reportable. Using Congo red is a safe method because it causes no adverse event. In terms of the efficacy of AC detection, a prospective study by Tóth *et al* assessed the efficacy of the Congo red technique in 106 patients with the maximal acid output of less than 6.9 mmol/hour in men and 5.0 mmol/hour in women. The accuracy of the Congo red method was as high as 0.98 (95% CI 0.93 to 0.99).⁶ Moreover, using endoscopic findings from OGD alone is not sensitive enough to detect early stages of gastritis that have AC conditions such as early staged autoimmune gastritis. The use of Congo red in combination with OGD can help endoscopists better diagnose AC and be more sensitive.^{7,8}

Other methods that can be used to diagnose AC were reported as follows. Measuring vitamin B₁₂ level is another method which can detect patients with vitamin B₁₂ deficiency. It is not the most efficient way because the threshold for vitamin B₁₂ deficiency is a value of less than 100 pg/mL, while simply being below average is less than 200 pg/mL.^{9,10} Examination of parietal cell antibodies and intrinsic factor antibodies is also useful in detecting patients with AC and PA, with intrinsic factor antibodies being more specific but less sensitive than anti-parietal cell antibodies. The sensitivity and specificity of anti-parietal cell antibodies were found to be at 81% and 90%, respectively, while sensitivity and specificity of anti-intrinsic factor antibodies were 27% and 100%, respectively.¹¹

In conclusion, results from this study which used the Congo red technique to detect AC during gastroscopy indicated that such a method could be easily used to diagnose AC. Nevertheless, given that the prevalence of AC in this current study was low, using vitamin B₁₂ level in

the high-risk group as a screening test seems to be more reasonable than the Congo red test. While the prevalence of AC in this current study was much less than that of AC reported in other studies, the characteristics of the population were different both in terms of ethnicity and types of population that were examined. The methods of testing were also different. Future prospective studies should be conducted to explore the benefits of using simple methods such as vitamin B₁₂ level to detect AC in the population over 50 years old.

Contributors KP: guarantor, data curation, formal analysis, writing—original draft, writing—review and editing. YS: data curation, writing—review and editing. CL: writing—review and editing. NN: data curation, writing—review and editing. YV: writing—review and editing. PK: data curation, formal analysis, writing—original draft, writing—review and editing.

Funding The authors have not declared a specific grant for this research from any funding agency in the public, commercial or not-for-profit sectors.

Competing interests None declared.

Patient consent for publication Not applicable.

Ethics approval Not applicable.

Provenance and peer review Not commissioned; externally peer reviewed.

Data availability statement Data are available on reasonable request.

Open access This is an open access article distributed in accordance with the Creative Commons Attribution Non Commercial (CC BY-NC 4.0) license, which permits others to distribute, remix, adapt, build upon this work non-commercially, and license their derivative works on different terms, provided the original work is properly cited, appropriate credit is given, any changes made indicated, and the use is non-commercial. See: <http://creativecommons.org/licenses/by-nc/4.0/>.

ORCID iD

Chawin Lopimpisuth <http://orcid.org/0000-0003-0308-4986>

REFERENCES

- Carmel R, Johnson CS. Racial patterns in pernicious anemia. Early age at onset and increased frequency of intrinsic-factor antibody in black women. *N Engl J Med* 1978;298:647–50.
- Bins M, Burgers PI, Selbach SG, *et al*. Prevalence of achlorhydria in a normal population and its relation to serum gastrin. *Hepatology* 1984;31:41–3.



- 3 Carmel R. Prevalence of undiagnosed pernicious anemia in the elderly. *Arch Intern Med* 1996;156:1097–100.
- 4 Jacobson DL, Gange SJ, Rose NR, *et al.* Epidemiology and estimated population burden of selected autoimmune diseases in the United States. *Clin Immunol Immunopathol* 1997;84:223–43.
- 5 Carmel R, Johnson CS, Weiner JM. Pernicious anemia in Latin Americans is not a disease of the elderly. *Arch Intern Med* 1987;147:1995–6.
- 6 Tóth E, Sjölund K, Thorsson O, *et al.* Evaluation of gastric acid secretion at endoscopy with a modified Congo red test. *Gastrointest Endosc* 2002;56:254–9.
- 7 Park JY, Lam-Himlin D, Vemulapalli R. Review of autoimmune metaplastic atrophic gastritis. *Gastrointest Endosc* 2013;77:284–92.
- 8 Neumann WL, Coss E, Ruge M, *et al.* Autoimmune atrophic gastritis—pathogenesis, pathology and management. *Nat Rev Gastroenterol Hepatol* 2013;10:529–41.
- 9 Langan RC, Zawistoski KJ. Update on vitamin B12 deficiency. *Am Fam Physician* 2011;83:1425–30.
- 10 Bailey RL, Carmel R, Green R, *et al.* Monitoring of vitamin B-12 nutritional status in the United States by using plasma methylmalonic acid and serum vitamin B-12. *Am J Clin Nutr* 2011;94:552–61.
- 11 Lahner E, Norman GL, Severi C, *et al.* Reassessment of intrinsic factor and parietal cell autoantibodies in atrophic gastritis with respect to cobalamin deficiency. *Am J Gastroenterol* 2009;104:2071–9.