


Closure of recurrent colovaginal fistulas using AMPLATZER occluder device

Joseph Simmons ¹, Ahmed Sherif,² Jason Mader,³ Saba Altarawneh,¹ Mehiar El-Hamdani,³ Wesam Frandah²

To cite: Simmons J, Sherif A, Mader J, *et al*. Closure of recurrent colovaginal fistulas using AMPLATZER occluder device. *BMJ Open Gastro* 2022;**9**:e000921. doi:10.1136/bmjgast-2022-000921

► Additional supplemental material is published online only. To view, please visit the journal online (<http://dx.doi.org/10.1136/bmjgast-2022-000921>).

Received 30 March 2022
Accepted 29 May 2022

ABSTRACT

A 79-year-old woman and a 92-year-old woman were referred to the gastroenterology department for management of persistent colovaginal fistula despite surgical and non-surgical management. Both patients had several hospitalisations for recurrent urinary tract infections. After failed surgical management and endoscopy using over-the-scope clipping, both patients underwent endoscopic closure using the Amplatzer cardiac septal occluder device. Both patients underwent successful closure and had no recurrence of symptoms at 6-month follow-up. Although there are several therapies available for persistent colovaginal fistulas, most involve multiple sessions and have high recurrence rate. There have been reports in the literature of cardiac septal occluders being used in the management of upper gastrointestinal tract fistulas, but few cases exist explaining their role in the management of colovaginal fistulas. Our cases demonstrate that cardiac septal occluders may be a viable option for management of fistulas and warrants further studies to reproduce its effectiveness and safety.

INTRODUCTION

The term colovaginal fistula describes an abnormal connection between the colon and the vagina. While the clinical presentation is variable, most patients present with passage of gastrointestinal (GI) contents or gas into the vagina, pelvic pain, or recurrent urinary tract infections (UTIs). Several aetiologies have been described including diverticular disease, malignancy of the GI or GU tracts, radiotherapy to the pelvis, or previous pelvic surgery (ie, hysterectomy).¹⁻⁴ Colovaginal fistula is a clinical diagnosis supported by imaging such as CT with contrast enema and endoscopic evaluation.³ Treatment options vary and include both surgical and endoscopic techniques. Endoscopic techniques include use of clips, cap mounted clips, self-expanding metal stents, sealants and endoscopic sutures. However, these therapies have varying success rates and often result in multiple procedures.^{1 2 4} Cardiac septal occluders (CSOs) are typically used in the

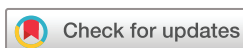closure of atrial septal defects and ventricular septal defects. There have been some reports of CSO use in closure of upper GI fistulas.^{1 2} We present two cases of colovaginal fistula closure using the Amplatzer cardiac septal defect occluder.

CASE REPORT

The first case is a 79-year-old woman with hypertension, morbid obesity, GERD and colovaginal fistula. Patient originally underwent a robotic assisted laparoscopic sigmoidectomy with colorectal anastomosis and diverting ileostomy. She had several hospitalisations since the time of surgery due to recurrent UTIs secondary to persistent colovaginal fistula. Initial closure was attempted using over-the-scope clipping and argon plasma coagulation, but she had recurrence of her symptoms and persistent fistula. She was then hospitalised with entero-cutaneous fistula around her ostomy site which necessitated exploratory laparotomy with partial small bowel resection, takedown of her diverting ileostomy and an end ileostomy. Barium enema was ordered which showed a colovaginal fistula at the distal sigmoid colon (figure 1A). Gastroenterology was consulted for alternative fistula closure options.

A colonoscopy was performed which demonstrated the colocolonic anastomosis where a fistula was noted near the anastomosis line. The scope was removed, cleaned and advanced through the vagina and the fistulous opening was identified (figure 1B). Using an XL tandem catheter, a 0.025 inch by 450 cm straight VISI glidewire was advanced through the vaginal end of the fistula, through the colon and out the anus. Under direct and fluoroscopic visualisation, an Amplatzer PFO occluder was deployed. Final fluoroscopic images showed no further extravasation of contrast (please refer to online supplemental video 1).

The second case is a 92-year-old woman with hypertension, previous stroke, recurrent



© Author(s) (or their employer(s)) 2022. Re-use permitted under CC BY-NC. No commercial re-use. See rights and permissions. Published by BMJ.

¹Department of Internal Medicine, Marshall University, Huntington, West Virginia, USA

²Department of Gastroenterology and Hepatology, Marshall University, Huntington, West Virginia, USA

³Department of Cardiovascular Services, Marshall University, Huntington, West Virginia, USA

Correspondence to

Dr Joseph Simmons;
simmons128@marshall.edu

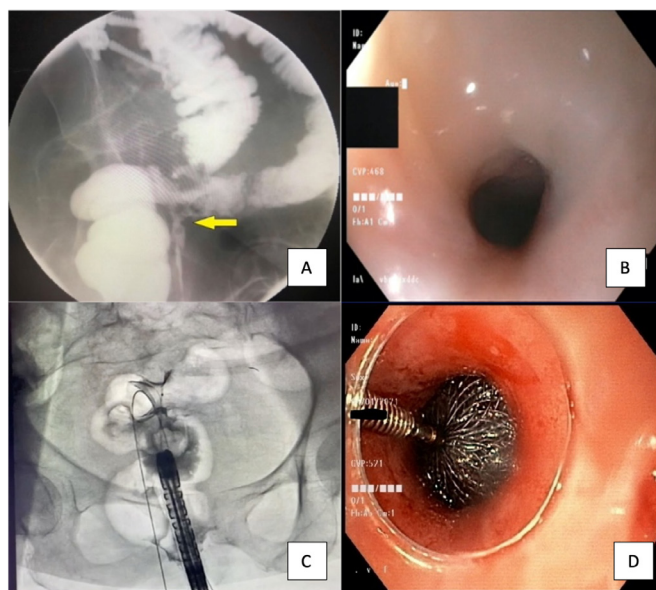


Figure 1 (A) Barium enema showing colovaginal fistula in the distal sigmoid colon (yellow arrow). (B) Endoscopic view of fistulous opening in the vagina. (C) Fluoroscopy showing delivery of cardiac septal occluder sheath. (D) Successful deployment of the Amplatzer CSO device. CSO, cardiac septal occluder.

diverticulitis status postpartial sigmoidectomy and recurrent UTIs secondary to colovaginal fistula. She had failed several surgical options, the most recent of which was a diverting colostomy to bypass the fistula given her recurrent UTIs. After discussion of risks and benefits, the decision was made to proceed with endoscopic closure of the fistula using the Amplatzer PFO occluder in conjunction with interventional cardiology.

An endoscope fitted with a cap was advanced into the vagina revealing a 7 mm hole in the vaginal cuff. A 0.035 Jagwire was passed through the opening and into the sigmoid colon. Contrast was injected showing the fistulous tract. The wire was passed through the sigmoid and out of the anus and secured. Colonoscopy was performed to confirm the location of the colonic side of the fistula. An eight-french PFO delivery sheath was introduced into the sigmoid colon under fluoroscopic guidance (figure 1C). A 16mm Amplatzer PFO occluder was deployed under both direct and fluoroscopic guidance (figure 1D). Contrast was then injected with no further extravasation.

DISCUSSION

Colovaginal fistula is a rare condition. Aetiologies include diverticular disease, iatrogenic, inflammatory bowel disease, neoplasm and obstetric causes.¹ Colovaginal fistula complicates ~14% of diverticulitis after an acute episode.³ Identifying the fistula aetiology, location and size is important for choosing the most suitable treatment modality.

Conventional endoscopic therapies used to treat GI fistulas include the use of clips, cap mounted clips,

self-expandable metal stents, endoscopic sutures, internal endoscopic drainage using double pigtail stents and endoscopic vacuum therapy.⁴ These techniques require multiple sessions and the recurrence rate is relatively high. The limitations of the current therapeutic approaches necessitate investigation into use of other modalities for management of GI tract fistulas, such as CSOs.^{1,2}

CSOs are shape-memory, self-expanding double-disc closure devices composed of nitinol and interwoven polyester.² Although data is limited regarding the use of CSOs, these properties make it useful in treating fistulas that are difficult to manage using traditional endoscopic techniques.⁵ The nitinol structure with interwoven polyester liner is thought to facilitate tissue in-growth while sealing the fistula tract. These features promote CSO device to manage fistulas with irregular margins and those in scarred or edematous tissues, which are less amenable to clipping, suturing or covering.²

CSOs have been used in various GI tract fistulas as reported in a systemic review by De Moura *et al* in *Clinical Endoscopy*.² For their review, 25 574 studies were screened for retrieval. There were 29 full text articles assessed for eligibility and of those, 19 were selected. Table 1 summarises the results from their review article. The review showed a 100% technical success rate, 77.27% clinical success rate, and 22.72% adverse event rate with no deaths related to the off-label use of CSOs in closure of GI tract fistulas.²

In our cases, the colovaginal fistulas were managed successfully with the Amplatzer CSO. To our knowledge, the only other cases involving the use of the Amplatzer CSO for fistulous closure of a colovaginal fistula were reported by Alabaz and Topal in Turkey and Sadiq *et al* in Michigan.¹³ Limitations to this method may include cost or availability of the CSO as well as availability of interventional cardiology and an endoscopist trained in advanced endoscopic procedures.

Our cases demonstrate the challenges involved in the treatment of colovaginal fistulas. Older patients with multiple comorbidities are often not ideal surgical candidates or have failure surgical management in the past, making non-invasive options necessary. The Amplatzer CSO was successfully used in both of our patients for closure of the colovaginal fistulas with resolution of symptoms at 6-month follow-up. Prior to closure, both patients experienced recurrent UTIs as well as abdominal pain and vaginal discharge. At 6-month follow-up, one patient reported minimal vaginal spotting but no mucous or feculent discharge. The other patient had less frequent UTIs and no further hospitalisations for UTI at 6-month follow-up. One patient had follow-up colonoscopy at 2 months to confirm fistula closure which showed no contrast communicating between the bowel and the vagina. Both patients had follow-up barium studies at 6 months. One study showed a small leak anterior to the cardiac occluder device but no contrast extravasation into the bowel. The other showed no leak and no

Table 1 Summary of published cases involving CSOs and GI tract fistulas—adapted from De Moura *et al*²

Study authors	Patient demographics	Type of fistula	Follow-up	Achievement of fistula closure	Complications
Rabenstein <i>et al</i> (2006)	70-year-old, female	Esophagorespiratory	6 months	Yes	Migration of the device, however ultimately had fistula closure
Green <i>et al</i> (2008)	69-year-old, male	Esophagorespiratory	5 weeks	Yes	None
Boulougouri <i>et al</i> (2009)	57-year-old, male	Duodenocutaneous	5 months	Yes	None
Melmed <i>et al</i> (2009)	82-year-old, female	Gastrocolic	4 months then 18 months	Initially failed closure, repeat with a different CSO led to closure	Device collapse into the colon at first follow-up
Coppola <i>et al</i> (2010)	83-year-old, unspecified	Tracheoesophageal	2 months then 10 months	Yes, but with self expanding stents after CSO migration	Larger fistula with migration of the device
Kouklakis <i>et al</i> (2010)	58-year-old, male	Gastrocolic	1 week	Yes	Small leak on imaging
Baron (2010)	38-year-old, female	Gastrocolic	6 weeks	Yes	None
Repici <i>et al</i> (2010)	58-year-old, male	Tracheoesophageal	8 months	Yes	None
Lee <i>et al</i> (2011)	68-year-old, male	Esophagorespiratory	1 month	Yes	None
Cardoso <i>et al</i> (2012)	60-year-old, male	Esophagomediastinal	6 weeks	Yes	None
Kadlec <i>et al</i> (2013)	63-year-old, female	Esophagorespiratory	12 days then 9 months	Yes but with surgery after initial failure of CSO	None
Kumbhari <i>et al</i> (2014)	50-year-old, female	Leak at gastrectomy staple line	8 weeks	Yes	None
Kumbhari <i>et al</i> (2014)	72-year-old, female	Tracheoesophageal	6 weeks	Yes	None
Wiest <i>et al</i> (2014)	40-year-old, male	Leak of sleeve gastrectomy	1 year	Yes	None
Odemis <i>et al</i> (2015)	35-year-old, male	Leak at gastrectomy staple line	6 month	Yes	None
Cohen-Atsmoni <i>et al</i> (2015)	Two patients, unspecified	Tracheoesophageal	4 years, 2 weeks	Yes for patient 1, no for patient 2	Patient two was critically ill and died of fungal sepsis
Subtil <i>et al</i> (2016)	63-year-old, male	Tracheoesophageal	4 months	Yes	None
Fernandez-Urien <i>et al</i> (2016)	51-year-old, male	Esophagobronchial	9 months	Yes	None
Mejia Perez <i>et al</i> (2016)	55-year-old, male	Esophagopleural	4 weeks	Yes	None
CSO, cardiac septal occluder; GI, gastrointestinal.					

extravasation of contrast. Patients undergoing this procedure should be followed up at 6 months postprocedure to ensure resolution of symptoms and fistula closure. Subsequent endoscopic evaluation with colonoscopy can be used on an as-needed basis if symptoms persist or if fistulous closure was not demonstrated on follow-up barium studies. These cases demonstrate that this device may be a viable option for non-surgical management of fistulas and warrants further studies to reproduce its effectiveness and safety.

Acknowledgements We would like to thank the patients involved in this case report for allowing us to publish and educate other physicians on the treatment approach used in their cases.

Contributors JS wrote the initial draft and finalised the manuscript for submission. SA contributed strongly to the discussion section of the manuscript. All authors contributed to the manuscript and read the final draft prior to submission. WF, JM, ME-H and AS were present and contributed to the procedure described in the manuscript.

Funding The authors have not declared a specific grant for this research from any funding agency in the public, commercial or not-for-profit sectors.

Competing interests None declared.

Patient consent for publication Consent obtained directly from patient(s)

Provenance and peer review Not commissioned; externally peer reviewed.

Data availability statement No data are available.

Supplemental material This content has been supplied by the author(s). It has not been vetted by BMJ Publishing Group Limited (BMJ) and may not have been

peer-reviewed. Any opinions or recommendations discussed are solely those of the author(s) and are not endorsed by BMJ. BMJ disclaims all liability and responsibility arising from any reliance placed on the content. Where the content includes any translated material, BMJ does not warrant the accuracy and reliability of the translations (including but not limited to local regulations, clinical guidelines, terminology, drug names and drug dosages), and is not responsible for any error and/or omissions arising from translation and adaptation or otherwise.

Open access This is an open access article distributed in accordance with the Creative Commons Attribution Non Commercial (CC BY-NC 4.0) license, which permits others to distribute, remix, adapt, build upon this work non-commercially, and license their derivative works on different terms, provided the original work is properly cited, appropriate credit is given, any changes made indicated, and the use is non-commercial. See: <http://creativecommons.org/licenses/by-nc/4.0/>.

ORCID iD

Joseph Simmons <http://orcid.org/0000-0002-3684-784X>

REFERENCES

- 1 Sadiq O, Simmer S, Watson A, *et al*. Colovaginal fistula closure using a cardiac septal defect occluder. *VideoGIE* 2021;6:41–3.
- 2 De Moura DTH, Baptista A, Jirapinyo P, *et al*. Role of cardiac septal occluders in the treatment of gastrointestinal fistulas: a systematic review. *Clin Endosc* 2020;53:37–48.
- 3 Alabaz O, Topal U. Innovative technique for the closure of rectovaginal fistula using Amplatzer™ septal occluder. *J Evol Med Dent Sci* 2021;10:2225–7.
- 4 Cho J, Sahakian AB. Endoscopic closure of gastrointestinal fistulae and leaks. *Gastrointest Endosc Clin N Am* 2018;28:233–49.
- 5 Jiang P, Liu J, Yu D, *et al*. Closure of nonmalignant tracheoesophageal fistula using an atrial septal defect occluder: case report and review of the literature. *Cardiovasc Intervent Radiol* 2015;38:1635–9.