

Supplemental Figure 1

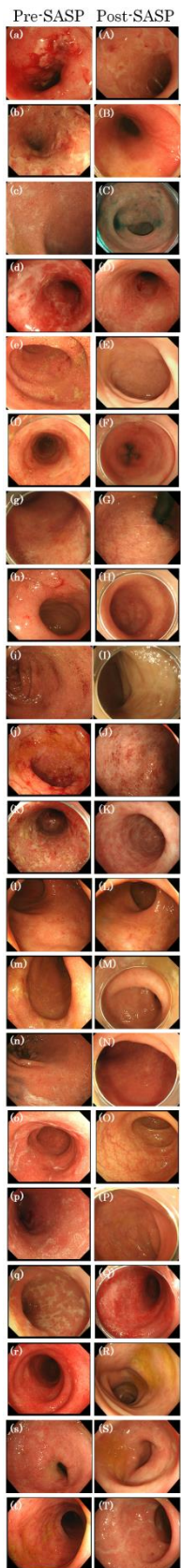


Figure Legend

Supplemental figure 1: Endoscopic findings of UC patients who could achieve clinical remission with SASP treatment.

(a)-(t): Endoscopic findings before administration of SASP treatment.

(A)-(T): Endoscopic findings after administration of SASP treatment.

In 20 of the 26 UC patients who could achieve clinical remission with SASP treatment, endoscopic examination was performed before and after initiating treatment with SASP. Of the remaining six patients, one was accidentally dead before re-examination with endoscopy. The remaining five patients with UC could not be re-evaluated with endoscopy after initiating treatment with SASP, since SASP treatment has initiated only in recent months. In the 20 UC patients evaluated with endoscopic examination, 15 (75%) patients could achieve mucosal healing, such as Mayo-0, 1, after administrating SASP.