

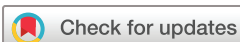# Tofacitinib and faecal microbiota transplantation in treating checkpoint inhibitor-induced enterocolitis: case report

Rikke Boedker Holmstroem <sup>1</sup>, Emilie Kristine Dahl <sup>2</sup>, Morten Helms <sup>3</sup>, Henrik Vedel Nielsen <sup>4</sup>, Janne Bayer Andersen,<sup>5</sup> Jacob Tveiten Bjerrum <sup>2,6</sup>, Inge Marie Svane <sup>1,6</sup>, Eva Ellebaek <sup>1,6</sup>, Jakob Benedict Seidelin <sup>2,6</sup>

**To cite:** Holmstroem RB, Dahl EK, Helms M, *et al.* Tofacitinib and faecal microbiota transplantation in treating checkpoint inhibitor-induced enterocolitis: case report. *BMJ Open Gastro* 2022;**9**:e000989. doi:10.1136/bmjgast-2022-000989

► Additional supplemental material is published online only. To view, please visit the journal online (<http://dx.doi.org/10.1136/bmjgast-2022-000989>).

Received 12 July 2022  
Accepted 2 December 2022



© Author(s) (or their employer(s)) 2022. Re-use permitted under CC BY-NC. No commercial re-use. See rights and permissions. Published by BMJ.

For numbered affiliations see end of article.

## Correspondence to

Prof, Dr Jakob Benedict Seidelin;  
Jakob.Benedict.Seidelin@regionh.dk

## ABSTRACT

**Background** Immune checkpoint inhibitors (ICIs) can induce a wide range of immune-related adverse events (irAEs), potentially affecting any organ. ICI-induced colitis is a frequently reported irAE, whereas enteritis is rare and not well documented.

**Case presentation** We are presenting a patient with metastatic melanoma who developed severe ICI-induced enterocolitis multirefractory for glucocorticoids, infliximab and vedolizumab, partially responding to faecal microbiota transplantation and final complete response to tofacitinib.

**Conclusion** This case supports that tofacitinib may be an (other) effective agent in managing multirefractory ICI-induced diarrhoea caused by colitis and/or enteritis.

## INTRODUCTION

Severe colitis occurs in up to 10% of patients treated with immune checkpoint inhibitors (ICIs). Colitis is a commonly reported immune-related adverse event (irAE) and contributes to the highest number of discontinuations, hospitalisation and fatal irAEs.<sup>1</sup> In contrast, enteritis is a rare occurrence with diarrhoea as a common symptom. No exact approach for the management of ICI-induced enteritis exists. The standard of care for ICI-induced colitis is an initiation of glucocorticoids. If symptoms persist, the use of infliximab or vedolizumab is recommended.<sup>2</sup> However, this will not reduce the inflammation in a subset of patients. In addition, no strict consensus exists regarding initiation, dose and duration of immunosuppressives. A few cases have reported successful outcomes with tofacitinib (inhibits JAK1/3), ustekinumab (antibody targeting interleukin-12 and interleukin-23), tacrolimus (macrolide calcineurin inhibitor), tocilizumab (interleukin-6-receptor antibody) and faecal microbiota transplantation (FMT) for

treatment of ICI-induced colitis. We present a rare case of ICI-induced enterocolitis multirefractory to the best supportive care, glucocorticoids, infliximab, vedolizumab and FMT, who had a prompt response to tofacitinib therapy.

## CASE PRESENTATION

A 62-year-old man with metastatic melanoma developed non-bloody diarrhoea up to 20 times per day after ipilimumab and nivolumab (ipi/nivo). He had no medical history and was diagnosed with cutaneous melanoma in 2009. In September 2019, he had a tumour-induced partial intestinal obstruction. A small bowel resection was performed with the removal of a 7×4×3 cm melanoma metastasis, BRAF wild type. He declined adjuvant treatment with nivolumab but relapsed and received pembrolizumab; adoptive cell therapy with tumour-infiltrating lymphocytes (ClinicalTrials.gov id NCT02278887); and finally, ipi/nivo and whole-brain radiotherapy. During pembrolizumab, he had capsule endoscopic-diagnosed duodenitis treated with peroral glucocorticoids 0.5 mg/kg/day. In July 2021, treatment with ipi/nivo was initiated. After four cycles, he had cancer progression (including lymph nodes, lung and brain metastasis) and suffered from epileptic seizures treated with prednisolone and levetiracetam.

In October 2021, 3 weeks after the last dose of ipi/nivo, the patient developed non-bloody diarrhoea up to 20 times per day (output >4L/day), equal to grade 4 at Common Terminology Criteria for Adverse Events (CTCAE) V.5.0 and was admitted to hospital. The physical examination was normal. Blood samples showed prerenal acute kidney failure

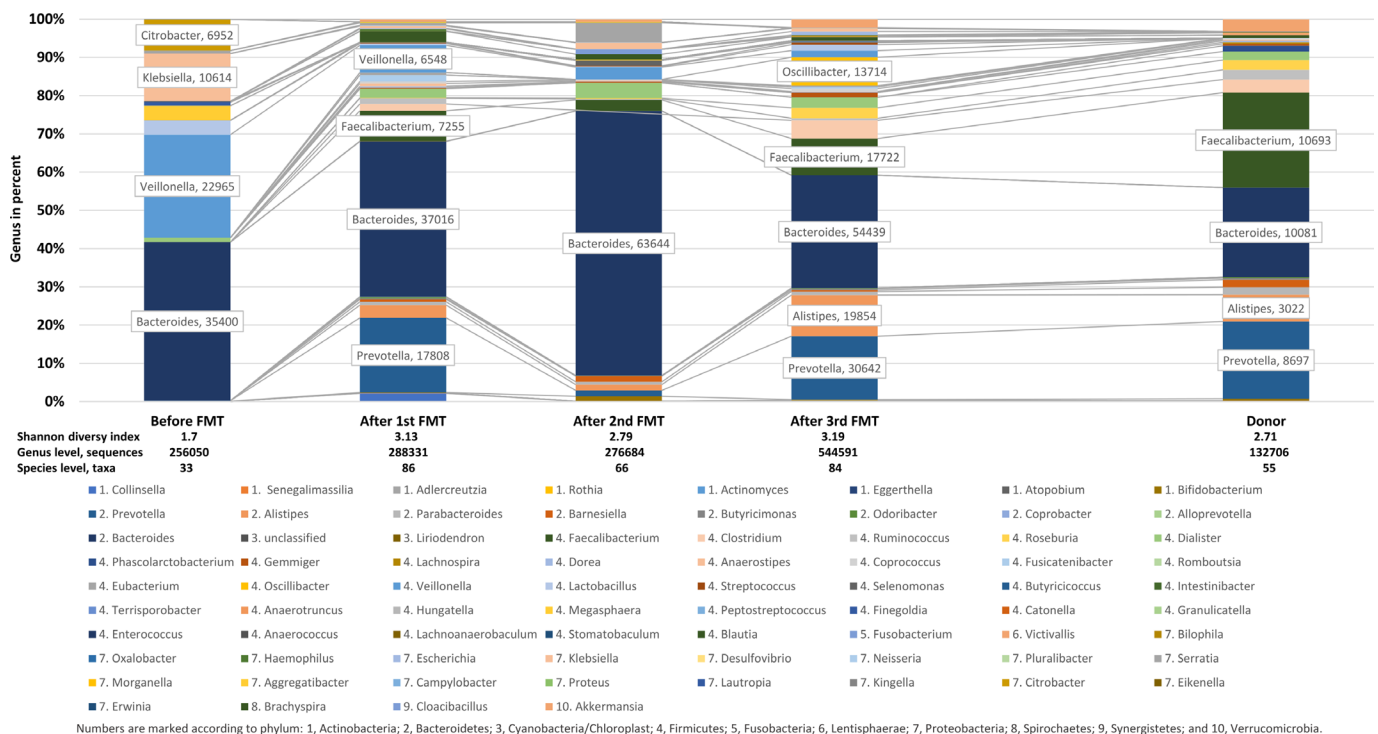
(creatinine 359 µmol/L, normal range 60–105). Faecal calprotectin was 694 µg/g (normal range <50 µg/g). Stool cultures (online supplemental file), diarrhoeagenic *Escherichia coli* and *Clostridioides difficile*; parasites; virus; antigen test for cytomegalovirus and Epstein-Barr were negative. CT showed increased oedema around the pancreas and the intestines. He had no abdominal pain, clinical signs of pancreatitis or adhesions after prior surgery.

An upper endoscopy and ileocolonoscopy were macroscopic normal. Biopsies were taken from all sites. Minor erosions, partial villous atrophy, increased number of lymphocytes and cryptitis were observed in the duodenum. The colon surface was flattened without ulcerations but with widespread cryptitis, intraepithelial lymphocytes and numerous crypt apoptosis. The colonic lamina propria had increased cellularity of mixed inflammatory cells with lymphocyte infiltrates. A capsule endoscopy showed signs of enteritis. Microscopic lymphocytic colitis and duodenitis induced by ICIs were diagnosed. Findings are presented in online supplemental figure S1.

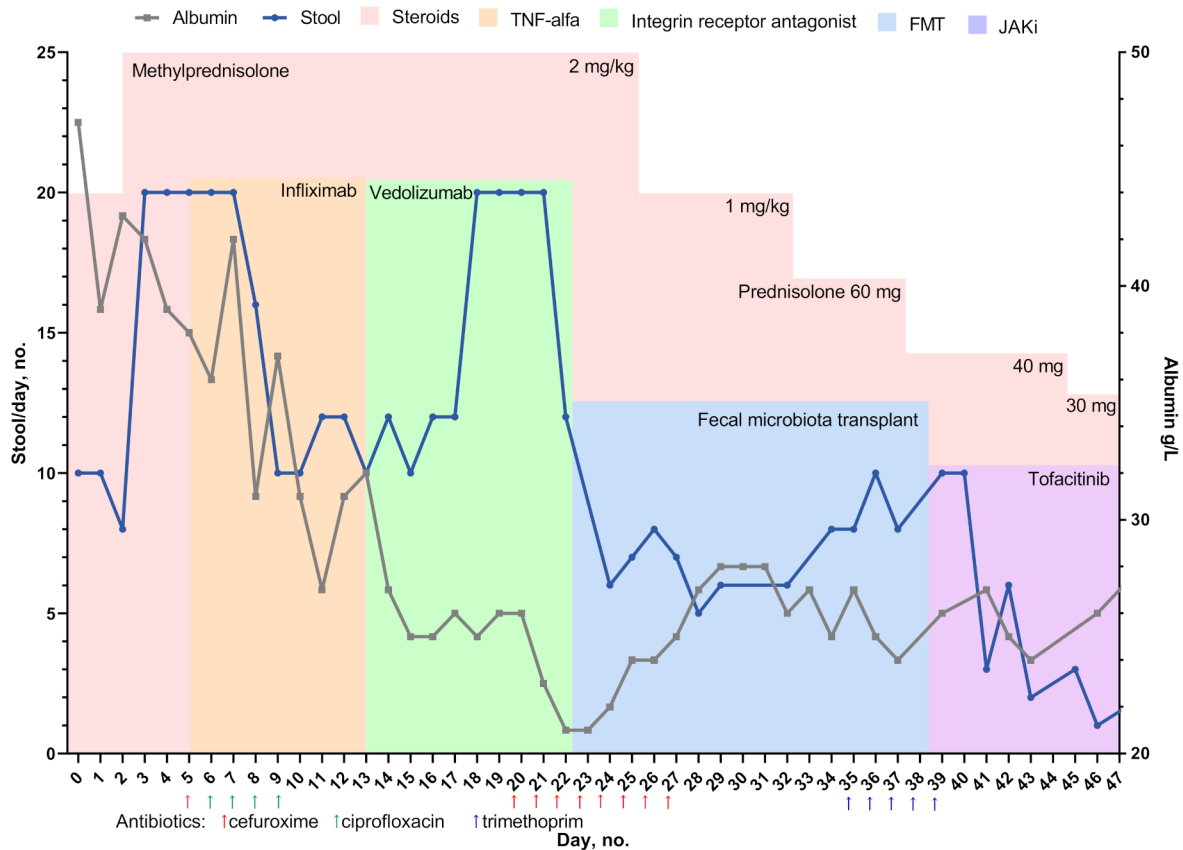
## MANAGEMENT OF IR-COLITIS

ICIs were stopped, intravenous fluids and intravenous methylprednisolone 1 mg/kg/day were initiated on the day of admission. On day 2, methylprednisolone was increased to 2 mg/kg/day, and on day 5, treatment with infliximab 5 mg/kg and ciprofloxacin

(indication: urinary tract infection) were added. On day 8, the second treatment of infliximab 10 mg/kg was given. On day 13, the patient received vedolizumab (300 mg). However, he still had a sizeable watery output and needed large volume intravenous rehydration daily, including magnesium and phosphate substitution. Stool cultures were repeated (online supplemental file), and the patient tested for gluten intolerance, without explanation for the patient's diarrhoea. Maximum supportive medication with loperamide (24 mg/day), octreotide (100 µg/day), pantoprazole (80 mg/day), opium (5 mg up to 12 times/day) and cholestyramine (12 g/day) had no effect. According to local guidelines, acute FMT was initiated on day 22 (universal donor from local stool biobank, oral administration every fifth day repeated on day 27 and day 32). During FMT a decreased frequency of diarrhoea, CTCAE grade 2–3, was observed and methylprednisolone dose was reduced. Faecal microbiota data were obtained before FMT and at every transplantation (figure 1, online supplemental methodology). He received antibiotics (days 20–27, cefuroxime 1.5 g ×3/day; days 35–39, trimethoprim 200 mg ×2/day) due to a urinary tract infection with *E. coli* during FMT. However, the frequency of diarrhoea and the level of C-reactive peptide increased on day 38 (online supplemental figure S2). Stool cultures for bacteria, viruses and parasites were repeated (online supplemental



**Figure 1** Microbiota composition by genus before and after faecal microbiota transplantation (FMT) compared with donor. After the first FMT, the Shannon Diversity Index increased from 1.7 to 3.13. It maintained high throughout the following FMT and ended at 3.19. Likewise, bacteria and archaea at the species level doubled in sequence reads from 256.050 before FMT to 544.591 bacterial reads annotated at the species level after the third FMT and tripled in the number of unique taxa identified, from 33 to 84. A more heterogeneous composition with an increasing number of *Bacteroidetes* (primarily dominated by *Bacteroides* before FMT, adding *Prevotella* and *Alistipes* after FMT) and *Firmicutes* were observed.



**Figure 2** Course of treatment. The patient’s diarrhoea started after fourth cycle of ipilimumab and nivolumab during prednisolone treatment (25 mg). On day 0, treatment with methylprednisolone was initiated. Due to a steroid-refractory condition, infliximab was added on day 5 and day 8. He then switched to vedolizumab on day 13. FMT was initiated on day 22 repeated on day 27 and day 32. During FMT, a partial reduction of diarrhoea frequency was noted; however, antibiotic treatments were given twice. The frequency of diarrhoea increased, and he switched to tofacitinib on day 38 with a prompt response within 3–4 days. FMT, faecal microbiota transplantation.

file)—all were negative. Therefore, tofacitinib (10 mg two times per day) peroral was added. He achieved normal stool on day 42 and was discharged. **Figure 2** presents a course of medical treatment, number of stools and serum albumin.

Three weeks later, he was hospitalised with CT-diagnosed pneumonia and pulmonary embolism but no radiologic signs nor symptoms of colitis. He stopped tofacitinib due to contraindications and did not relapse with diarrhoea during the 4 months of follow-up. He died 12 weeks after discharge due to cancer progression.

## DISCUSSION

In this case, glucocorticoids, infliximab and vedolizumab did not affect stool frequency. The FMT may have been temporally linked with diarrhoea resolution; however, tofacitinib most effectively treated the patient’s severe multirefractory enterocolitis. To the best of our knowledge, no case of severe multirefractory ICI-induced enterocolitis treated with FMT followed by tofacitinib has previously been described.

Tofacitinib is approved for treating rheumatoid arthritis and ulcerative colitis with inadequate response to tumour

necrosis factor inhibitors. Treatment of ICI-induced colitis with tofacitinib has been reported successful in four patients without interfering with cancer immune surveillance; however, most of these patients had achieved their anticancer responses before treatment.<sup>3</sup>

A shift in gut microbial composition, including decreased bacterial diversity with a lowering Shannon diversity index, has been associated with ICI-induced colitis. We observed an increased Shannon Diversity Index during FMT with decreasing stool frequency. Concomitant antibiotics may have affected the microbial composition, causing antibiotic-associated diarrhoea that, combined with a reduced prednisolone dose, may have worsened the patient’s diarrhoea. We cannot exclude that FMT and tofacitinib or tofacitinib alone decreased the frequency of diarrhoea nor those antibiotics harmed the microbial composition.

Both FMT and tofacitinib are described to be considered in ICI-induced colitis refractory to glucocorticoids, infliximab and vedolizumab.<sup>2</sup> Tofacitinib is an oral therapy with fast onset, short half-life, and therefore, more attractive. Tofacitinib inhibits the JAK-pathway that, may downregulate PD-L1 expression, creating a theoretical risk of acquired resistance to PD-1 blockade.<sup>4</sup> Vice

versa, downregulated expression of PD-L1 could potentially help overcome the immune resistance frequently occurring in melanoma patients; this has yet to be clarified. FMT may support ICI therapies, but the availability is a limiting factor.<sup>5</sup> In this case, FMT was prescribed by national experts in FMT as ‘off-label use,’ which made rapid initiation possible. Due to the risk of cancer progression, we advise caution before adding tofacitinib to ICI-induced colitis in patients with cancer.

This case supports tofacitinib as an (other) effective agent in managing multirefractory ICI-induced diarrhoea caused by colitis and/or enteritis. Still, the risk of thromboembolic events and infections should be closely monitored, especially in patients with cancer. Further, caution should be taken as tofacitinib may potentially downregulate PD-L1 expression.

#### Author affiliations

<sup>1</sup>National Center of Cancer Immune therapy (CCIT-DK), Department of Oncology, Copenhagen University Hospital, Herlev, Denmark

<sup>2</sup>Department of Gastroenterology, Copenhagen University Hospital, Herlev, Denmark

<sup>3</sup>Department of Infectious Diseases, Copenhagen University Hospital, Hvidovre, Denmark

<sup>4</sup>Department of Microbiology and Infection Control, Statens Serum Institut, Copenhagen, Denmark

<sup>5</sup>Department of Pathology, Copenhagen University Hospital, Herlev, Denmark

<sup>6</sup>Department of Clinical Medicine, University of Copenhagen Faculty of Health and Medical Sciences, Copenhagen, Denmark

**Contributors** Conducting the study: RBH, EKD, JTB and JBS. Collecting and/or interpreting data: all. Drafting the manuscript: RBH and EKD.

**Funding** The authors have not declared a specific grant for this research from any funding agency in the public, commercial or not-for-profit sectors.

**Competing interests** RBH has received speaking honoraria from BPNO via BMS. EKD has received honoraria from Tillotts and MSD as speaker. Within the last two years, IMS has received honoraria for consultancies and lectures from IO Biotech, Novartis, MSD, Pierre Fabre, BMS, Novo Nordisk, TILT Bio; research grants from IO Biotech, BMS, Lytix, Adaptimmune, TILT Bio. EES received honoraria from BMS, Pierre Fabre, Novartis for consultancies and lectures, and travel/conference expenses from MSD. JBS has received research grants from Takeda and the Capital Region Denmark, and has been a national coordinator of studies from AbbVie, Arena Pharmaceuticals, Ely Lilly, and Boehringer Ingelheim—none of these pertain to the research submitted here.

**Patient consent for publication** Consent obtained directly from patient(s)

**Provenance and peer review** Not commissioned; externally peer reviewed.

**Data availability statement** All data relevant to the study are included in the article or uploaded as online supplemental information.

**Supplemental material** This content has been supplied by the author(s). It has not been vetted by BMJ Publishing Group Limited (BMJ) and may not have been peer-reviewed. Any opinions or recommendations discussed are solely those of the author(s) and are not endorsed by BMJ. BMJ disclaims all liability and responsibility arising from any reliance placed on the content. Where the content includes any translated material, BMJ does not warrant the accuracy and reliability of the translations (including but not limited to local regulations, clinical guidelines, terminology, drug names and drug dosages), and is not responsible for any error and/or omissions arising from translation and adaptation or otherwise.

**Open access** This is an open access article distributed in accordance with the Creative Commons Attribution Non Commercial (CC BY-NC 4.0) license, which permits others to distribute, remix, adapt, build upon this work non-commercially, and license their derivative works on different terms, provided the original work is properly cited, appropriate credit is given, any changes made indicated, and the use is non-commercial. See: <http://creativecommons.org/licenses/by-nc/4.0/>.

#### ORCID iDs

Rikke Boedker Holmstroem <http://orcid.org/0000-0002-5476-9937>

Emilie Kristine Dahl <http://orcid.org/0000-0002-1383-5619>

Morten Helms <http://orcid.org/0000-0002-1140-0021>

Henrik Vedel Nielsen <http://orcid.org/0000-0002-6773-1874>

Jacob Tveiten Bjerrum <http://orcid.org/0000-0002-6249-3889>

Inge Marie Svane <http://orcid.org/0000-0002-9451-6037>

Eva Ellebaek <http://orcid.org/0000-0001-6748-9232>

Jakob Benedict Seidelin <http://orcid.org/0000-0003-3230-7966>

#### REFERENCES

- 1 Abu-Sbeih H, Ali FS, Wang X, *et al*. Early introduction of selective immunosuppressive therapy associated with favorable clinical outcomes in patients with immune checkpoint inhibitor-induced colitis. *J Immunother Cancer* 2019;7:93.
- 2 Schneider BJ, Naidoo J, Santomaso BD, *et al*. Management of immune-related adverse events in patients treated with immune checkpoint inhibitor therapy: ASCO guideline update. *J Clin Oncol* 2021;39:4073–126.
- 3 Bishu S, Melia J, Sharfman W, *et al*. Efficacy and outcome of tofacitinib in immune checkpoint inhibitor colitis. *Gastroenterology* 2021;160:932–4.
- 4 Luo N, Formisano L, Gonzalez-Ericsson PI, *et al*. Melanoma response to anti-PD-L1 immunotherapy requires JAK1 signaling, but not JAK2. *Oncoimmunology* 2018;7:e1438106.
- 5 Baruch EN, Youngster I, Ben-Betzalel G, *et al*. Fecal microbiota transplant promotes response in immunotherapy-refractory melanoma patients. *Science* 2021;371:602–9.