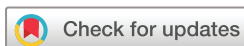

Efficacy of capsule endoscopy in patients with cirrhosis for the diagnosis of upper gastrointestinal lesions and small bowel abnormalities: a study protocol for prospective interventional study

Yoshinori Iwata,¹ Hiroki Nishikawa,^{1,2} Hirayuki Enomoto,¹ Kazunori Yoh,¹ Akio Ishii,¹ Yukihisa Yuri,¹ Noriko Ishii,¹ Yuho Miyamoto,¹ Kunihiro Hasegawa,¹ Chikage Nakano,¹ Ryo Takata,¹ Takashi Nishimura,¹ Nobuhiro Aizawa,¹ Yoshiyuki Sakai,¹ Naoto Ikeda,¹ Tomoyuki Takashima,¹ Hiroko Iijima,¹ Shuhei Nishiguchi^{1,2}

To cite: Iwata Y, Nishikawa H, Enomoto H, *et al.* Efficacy of capsule endoscopy in patients with cirrhosis for the diagnosis of upper gastrointestinal lesions and small bowel abnormalities: a study protocol for prospective interventional study. *BMJ Open Gastro* 2017;**4**:e000168. doi:10.1136/bmjgast-2017-000168

Received 2 August 2017
Revised 10 August 2017
Accepted 14 August 2017



¹Division of Hepatobiliary and Pancreatic disease, Department of Internal Medicine, Hyogo College of Medicine, Nishinomiya, Japan

²Center for Clinical Research and Education, Hyogo College of Medicine, Nishinomiya, Japan

Correspondence to

Dr Hirayuki Enomoto;
enomoto@hyo-med.ac.jp

ABSTRACT

Introduction and aims The role of capsule endoscopy (CE) in patients with liver cirrhosis (LC) has yet to be established; however, it is likely that it will remain a valuable diagnostic modality in several groups of patients with LC. The primary aims of the current prospective interventional study are to examine the prevalence for small bowel lesions and transit time of CE in the gastrointestinal tract in patients with LC with oesophageal varices (EVs) requiring endoscopic therapies.

Methods and analysis The current study will be a single-centre prospective interventional study. Our study participants are LC subjects with portal hypertension who were determined to be necessary for prophylactic endoscopic therapies for EVs. From the view point of safety, patients with gastrointestinal obstruction or fistula or those being suspected of having gastrointestinal obstruction or fistula will be excluded from our study. Patients with implanted medical devices will be also excluded. CE will be performed prior to prophylactic endoscopic therapies in the same hospitalisation and relevant images will be analysed after 8 hours by expert endoscopists. This study will continue to recruit until 50 participants.

Ethics and dissemination This study has received approval from the Institutional Review Board at Hyogo College of Medicine (approval no. 2680). The study protocol, informed assent form and other submitted files were reviewed and acknowledged. Final data will be publicly scattered regardless of the study results. A report releasing study results will be submitted for publication in a suitable journal after being finished in data collection.

Trial registration number UMIN000028433 (<https://upload.umin.ac.jp/>).

INTRODUCTION

Portal hypertension (PH) is a frequent manifestation in patients with liver cirrhosis (LC), and PH is associated with various pathological changes in the entire gastrointestinal tract.^{1–4} PH-related changes in the oesophagus, stomach, duodenum and colon are well described in the previous reports.^{1–7} In Japan, endoscopic therapies are central for the management of oesophageal varices (EVs), which is regarded as a major complication of LC.^{8–10} The standard endoscopic therapies for EVs in Japan are endoscopic injection sclerotherapy (EIS) and endoscopic band ligation (EBL).^{11 12}

Portal hypertensive gastroenteropathy (PHG) remains difficult to diagnose in patients with LC, with PH and limited diagnostic choices exist for the investigation of the small bowel in patients with LC.¹³ Capsule endoscopy (CE) is currently available as a minimally invasive imaging procedure which contributes significantly to the identification of small bowel abnormalities.^{14–16} CE revolutionised the evaluation for patients with obscure gastrointestinal bleeding because it allows reliable and non-invasive visibility of the mucosal surface in small bowels. Since 2001, CE has evolved into helpful diagnostic technology integrated in daily clinical practice.^{14–16} On the other hand, with the progression of LC, the peristaltic movement of the gastrointestinal tract is expected to decrease due

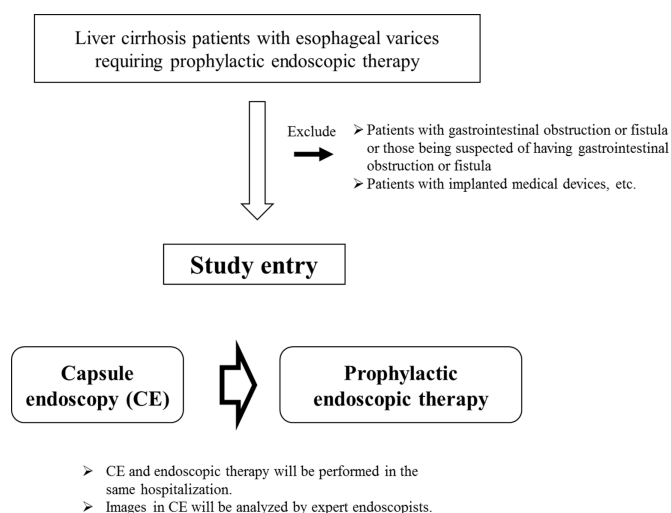


Figure 1 Study design.

to PHG, which may lead to the delay in excretion of capsule endoscopy.^{5 17–19} Small bowel capsule endoscopy (SBCE) has been utilised to characterise PHG and is valuable for the diagnosis of this condition in patients with LC who continue to bleed despite endoscopic treatment for EVs. The role of SBCE in PHG has yet to be established; however, it is likely that it will remain a valuable diagnostic modality in several groups of patients with LC.^{11–13} In addition, the sensitivity of CE is not currently sufficient to replace oesophago-gastroduodenoscopy (EGD) as a first exploration for patients with LC; however, given its high accuracy, it may have a certain role in patients with LC with refusal or contraindication for EGD.^{20–24}

Considering these backgrounds, in the current prospective interventional study, we will primarily aim to examine the prevalence for small bowel lesions and transit time of CE in the gastrointestinal tract in patients with LC with EVs requiring endoscopic therapies.

PATIENT ELIGIBILITY CRITERIA

The inclusion criteria for this study are as follows:

1. Gender is not limited.
2. Patients aged 18 years or more.
3. Patients with PH who were determined to be necessary for prophylactic endoscopic therapies for EVs such as EIS and EBL.

Patients will be excluded if they meet one or more of the following criteria.

1. Patients aged less than 18 years.
2. Patients with gastrointestinal obstruction or fistula or those being suspected of having gastrointestinal obstruction or fistula.
3. Patients with gastrointestinal stenosis in whom CE will be remained in the same place.
4. Patients with cardiac pacemakers or other implanted medical devices.
5. Patients with dysphagia.
6. Patients in whom consents for removal of remained CE are unable to be obtained.

7. Patients who are unable to receive open surgery.
8. Patients who were judged to be inappropriate for the study subjects.

STUDY PROTOCOL

- Study design: single-arm and open-label trial.

Our study participants are LC subjects with PH who were determined to be necessary for prophylactic endoscopic therapies for EVs. LC will be mainly determined by radiological findings such as CT and ultrasound (deformity of the liver surface, the presence of ascites, atrophy of the right lobe and/or compensatory swelling of the left lobe) and/or pathological findings. The current study will be a single-centre prospective interventional study. We will prospectively register appropriate candidates.

CAPSULE ENDOSCOPY

The CE is disposable and is naturally discharged at the time of defaecation. CE will be performed with a video capsule endoscopy device (PillCam SB2 plus capsule; Given Imaging, Tokyo, Japan) prior to prophylactic endoscopic therapies for EVs. CE and prophylactic endoscopic therapies of EVs for each participant will be performed in the same hospitalisation. Study participants will swallow the capsule in a sitting position with a solution of dimethicone after an overnight fast, without any other preparation.^{25–27} After 2 hours from swallowing of the capsule, participants will be allowed to drink clear liquids. After 4 hours from swallowing of the capsule, participants will be allowed to eat a light meal. After 8 hours, the sensor array and recording device will be removed and images will be analysed. Two expert endoscopists will make diagnoses after reaching an agreement with each other (figure 1).

Primary endpoints

1. Prevalence for small bowel lesions (small bowel lesions will be defined as follows: (a) vascular lesion or (b) ulcerative lesion). Tumour lesion will not be included for small bowel lesions in this study.
2. Transit time of CE in the gastrointestinal tract (oesophagus, stomach, duodenum and small bowel).

Secondary endpoints

1. Detection rate by capsule endoscopy for upper gastrointestinal lesions (upper gastrointestinal lesions will be defined as upper gastrointestinal varices or mucosal lesions whose presence was confirmed by EGD).

PROPHYLACTIC ENDOSCOPIC THERAPIES FOR EVS

Our protocol for prophylactic therapies for EVs is as reported previously.²⁸ Briefly, in our department, for patients with EVs positive for red colour signs or F2 or more EVs (medium or large varices), prophylactic endoscopic therapies will be in general considered. In patients with LC with Child-Pugh A, EIS monotherapy or EIS and EBL combination therapy will be selected, while in

patients with Child-Pugh B or C such as cases with severe ascites or hyperbilirubinaemia, EBL monotherapy will be chosen. Follow-up endoscopy after prophylactic endoscopic therapies will be considered after 1–3 months, and when eradication of EVs is incomplete, supplementary therapies will be carried out.²⁸

EXPECTED RISK FOR STUDY PARTICIPANTS

CE not being ejected outside the body within 2 weeks after initiation of the procedure indicates the stay of CE in the gastrointestinal tract. The incidence of this complication is reported to be 0.5%–2% in previous studies.^{19–29–31} When bowel obstruction-related clinical symptoms (vomiting or abdominal pain) occur and they will not be cured by conservative therapies, removal of capsule by small bowel endoscopy or open surgery is probably needed. This risk will be informed to each participant prior to study enrollment.

CASE REGISTRATION PERIOD

From July 2017 to March 2020 (there may be a change depending on registration status).

DATA COLLECTION

A research assistant will collect data elements from patient medical records, including:

Baseline data:

- gender, date of birth and age;
- height and body weight;
- vital signs;
- degree of drinking and smoking;
- cause for underlying liver diseases;
- previous treatments such as open surgery;
- comorbid conditions;
- baseline laboratory tests;
- presence or absence of ascites on radiologic findings; and
- presence or absence of abdominal symptoms.

STATISTICAL METHODS

Descriptive statistics

Data will be transferred to JMP V.13 software (SAS Institute, Cary, North Carolina, USA) and all data will be checked to ensure their consistency. Quantitative variables will be compared by unpaired t-test. Categorical variables will be compared using Pearson χ^2 test or Fisher's exact tests as appropriate.

Sample size

This study will not stipulate a sample size by statistical power calculations. However, considering that approximately 80 LC subjects will annually consult our department, the current study will continue to recruit until 50 participants.

DISCUSSION

Gastroenteropathy is a lesser recognised complication in patients with PH and consists of different changes in the mucosa of the small bowel which result in the appearance of vascular and inflammatory abnormalities.³² It can be a key factor for the development of anaemia in patients with LC, and recently an easy and non-invasive diagnosis is able to be made by CE. However, it is rarely considered for the management of patients with PH.^{32–34} Additionally, delay of transit time of CE in the gastrointestinal tract will be expected due to PHG-related decrease in the peristaltic movement.^{5 17–19} Thus, there will be urgent need for clarifying these issues. To the best of our knowledge, the current study is the first prospective interventional Japanese study to investigate the diagnostic usefulness of CE for gastrointestinal lesions in patients with LC with EVs requiring endoscopic therapies. From the view point of safety, CE and prophylactic endoscopic therapies for each participant will be performed in the same hospitalisation in this protocol.

One study drawback is that the current study will be based on a Japanese population, and additional investigations on different ethnic populations are required to further verify the efficacy of CE and extrapolate to races other than Japanese. Another drawback is that this study is not a randomised trial. However, if the effectiveness of CE in patients with LC is confirmed in this trial, useful information will be provided for clinicians.

ETHICS AND DISSEMINATION

Research ethics acknowledgement

This study has received acknowledgement from the Institutional Review Board at Hyogo College of Medicine (approval no. 2680). The study protocol, informed assent form and other submitted files were carefully reviewed and acknowledged. Trial registration number is UMIN000028433 (<https://upload.umin.ac.jp/>).

Confidentiality

On recruitment, the study assistant will give a unique scrambled identification number to each participant. Only the identification number will be used to identify participants. Data sheets and any printout of electronic files will be saved in a locked filing cabinet in a secure office in the Department of Hepatobiliary and Pancreatic disease, Department of Internal Medicine, Hyogo College of Medicine, Hyogo, Japan, with limited access.

Dissemination policy

Final data will be publicly scattered regardless of the study results. A report releasing study results will be submitted for publication in a suitable journal after completion of data collection.

Funding The current research will receive no specific grant from any funding agency in the public, commercial or not-for-profit organisations.

Competing interests None declared.

Patient consent Obtained.

Ethics approval Institutional Review Board at Hyogo college of medicine (approval no. 2680).

Provenance and peer review Not commissioned; externally peer reviewed.

Open Access This is an Open Access article distributed in accordance with the Creative Commons Attribution Non Commercial (CC BY-NC 4.0) license, which permits others to distribute, remix, adapt, build upon this work non-commercially, and license their derivative works on different terms, provided the original work is properly cited and the use is non-commercial. See: <http://creativecommons.org/licenses/by-nc/4.0/>

© Article author(s) (or their employer(s) unless otherwise stated in the text of the article) 2017. All rights reserved. No commercial use is permitted unless otherwise expressly granted.

REFERENCES

- Kozarek RA, Botoman VA, Bredfeldt JE, *et al.* Portal colopathy: prospective study of colonoscopy in patients with portal hypertension. *Gastroenterology* 1991;101:1192–7.
- Viggiano TR, Gostout CJ. Portal hypertensive intestinal vasculopathy: a review of the clinical, endoscopic, and histopathologic features. *Am J Gastroenterol* 1992;87:944–54.
- Krystallis C, Masterton GS, Hayes PC, *et al.* Update of endoscopy in liver disease: more than just treating varices. *World J Gastroenterol* 2012;18:401–11.
- Cárdenas A, Ginès P. Portal hypertension. *Curr Opin Gastroenterol* 2009;25:195–201.
- Cubillas R, Rockey DC. Portal hypertensive gastropathy: a review. *Liver Int* 2010;30:1094–102.
- Waterman M, Gralnek IM. Capsule endoscopy of the esophagus. *J Clin Gastroenterol* 2009;43:605–12.
- Toubia N, Sanyal AJ. Portal hypertension and variceal hemorrhage. *Med Clin North Am* 2008;92:551–74.
- Fukui H, Saito H, Ueno Y, *et al.* Evidence-based clinical practice guidelines for liver cirrhosis 2015. *J Gastroenterol* 2016;51:629–50.
- Miyaaki H, Ichikawa T, Taura N, *et al.* Endoscopic management of esophagogastric varices in Japan. *Ann Transl Med* 2014;2:42.
- Dai C, Liu WX, Jiang M, *et al.* Endoscopic variceal ligation compared with endoscopic injection sclerotherapy for treatment of esophageal variceal hemorrhage: a meta-analysis. *World J Gastroenterol* 2015;21:2534–41.
- Aoyama T, Oka S, Aikata H, *et al.* Small bowel abnormalities in patients with compensated liver cirrhosis. *Dig Dis Sci* 2013;58:1390–6.
- De Palma GD, Rega M, Masone S, *et al.* Mucosal abnormalities of the small bowel in patients with cirrhosis and portal hypertension: a capsule endoscopy study. *Gastrointest Endosc* 2005;62:529–34.
- Dabos KJ, Yung DE, Bartzis L, *et al.* Small bowel capsule endoscopy and portal hypertensive enteropathy in cirrhotic patients: results from a tertiary referral centre. *Ann Hepatol* 2016;15:394–401.
- Tziatzios G, Gkolfakis P, Dimitriadis GD, *et al.* Long-term effects of video capsule endoscopy in the management of obscure gastrointestinal bleeding. *Ann Transl Med* 2017;5:196.
- Kopylov U, Yung DE, Engel T, *et al.* Diagnostic yield of capsule endoscopy versus magnetic resonance enterography and small bowel contrast ultrasound in the evaluation of small bowel Crohn's disease: Systematic review and meta-analysis. *Dig Liver Dis* 2017;49:854–63.
- Niikura R, Yamada A, Maki K, *et al.* Associations between drugs and small-bowel mucosal bleeding: A multicenter capsule-endoscopy study. *Dig Endosc* 2017.
- Mekaroonkamol P, Cohen R, Chawla S. Portal hypertensive enteropathy. *World J Hepatol* 2015;7:127–38.
- Perini RF, Camara PR, Ferraz JG. Pathogenesis of portal hypertensive gastropathy: translating basic research into clinical practice. *Nat Clin Pract Gastroenterol Hepatol* 2009;6:150–8.
- Rondonotti E. Capsule retention: prevention, diagnosis and management. *Ann Transl Med* 2017;5:198.
- McCarty TR, Afinogenova Y, Njei B. Use of wireless capsule endoscopy for the diagnosis and grading of esophageal varices in patients with portal hypertension: a systematic review and meta-analysis. *J Clin Gastroenterol* 2017;51:174–82.
- Offman J, Fitzgerald RC. Alternatives to traditional per-oral endoscopy for screening. *Gastrointest Endosc Clin N Am* 2017;27:379–96.
- Krok KL, Wagennar RR, Kantsevov SV, *et al.* Esophageal capsule endoscopy is not the optimal technique to determine the need for primary prophylaxis in patients with cirrhosis. *Arch Med Sci* 2016;12:365–71.
- Aoyama T, Oka S, Aikata H, *et al.* Is small-bowel capsule endoscopy effective for diagnosis of esophagogastric lesions related to portal hypertension? *J Gastroenterol Hepatol* 2014;29:511–6.
- de Franchis R, Eisen GM, Laine L, *et al.* Esophageal capsule endoscopy for screening and surveillance of esophageal varices in patients with portal hypertension. *Hepatology* 2008;47:1595–603.
- Yung DE, Rondonotti E, Sykes C, *et al.* Systematic review and meta-analysis: is bowel preparation still necessary in small bowel capsule endoscopy? *Expert Rev Gastroenterol Hepatol* 2017;1–15.
- McAlindon ME, Ching HL, Yung D, *et al.* Capsule endoscopy of the small bowel. *Ann Transl Med* 2016;4:369.
- Hookey L, Louw J, Wiepjes M, *et al.* Lack of benefit of active preparation compared with a clear fluid-only diet in small-bowel visualization for video capsule endoscopy: results of a randomized, blinded, controlled trial. *Gastrointest Endosc* 2017;85:187–93.
- Nishikawa H, Yuri Y, Enomoto H, *et al.* Effect of psoas muscle mass after endoscopic therapy for patients with esophageal varices. *Medicine* 2017;96:e6868.
- Hosoe N, Naganuma M, Ogata H. Current status of capsule endoscopy through a whole digestive tract. *Dig Endosc* 2015;27:205–15.
- Health Quality Ontario. Capsule endoscopy in the assessment of obscure gastrointestinal bleeding: an evidence-based analysis. *Ont Health Technol Assess Ser* 2015;15:1–55.
- Esaki M, Matsumoto T, Watanabe K, *et al.* Use of capsule endoscopy in patients with Crohn's disease in Japan: a multicenter survey. *J Gastroenterol Hepatol* 2014;29:96–101.
- Egea Valenzuela J, Fernández Llamas T, García Marín AV, Alberca de Las Parras F, Carballo Álvarez F. Diagnostic and therapeutic features of small bowel involvement in portal hypertension. *Rev Esp Enferm Dig* 2017.
- Enns RA, Hookey L, Armstrong D, *et al.* Clinical practice guidelines for the use of video capsule endoscopy. *Gastroenterology* 2017;152:497–514.
- Yamamoto H, Ogata H, Matsumoto T, *et al.* Clinical practice guideline for enteroscopy. *Dig Endosc* 2017;29:519–46.